



## Paraspinal Gossypiboma Resembling an Abscess: A Case Report

### Abseye Benzeyen Paraspinal Spongema: Olgu Sunumu

Paraspinal Spongema / Paraspinal Gossypiboma

Süleyman Coşkun<sup>1</sup>, Özkan Arabacı<sup>1</sup>, Pınar Polat<sup>2</sup>, Mehmet Dumlu Aydın<sup>1</sup>

<sup>1</sup>Department of Neurosurgery, <sup>2</sup>Department of Radiology, Medical Faculty, Ataturk University, Erzurum, Turkey

#### Özet

45 yaşında erkek hasta 5 aydır devam eden bel ağrısı ve sol siyatalji yakınması ile başvurdu. 7 ay önce L4-5 disk hernisi nedeniyle ameliyat olmuştu. Bilgisayarlı tomografi (CT) ve manyetik rezonans görüntüleme (MRI) sol posterior paravertebral bölgede lokalize abse oluşumunu andıran tezat bir kitle lezyon tespit edildi. Paravertebral abse tanısı kondu ve lokal anestezi altında ultrasonografi rehberliğinde aspirasyon planlandı. Müdahale sırasında, iğne kavite içerisinde olmasına rağmen yeterince materyal aspire edilemedi. Böylece, cerrahi planlandı ve sol paraspinal bölgede spongema bulundu ve total çıkarıldı. Hasta sorunsuz iyileşti.

#### Anahtar Kelimeler

Spongema; Disk Cerrahisi; Paraspinal Apse

#### Abstract

A 45-year-old man presented with complaints of low back pain, sciatalgia on the left persisting for five months and fluid leakage from the wound. He had been operated for L4-5 disc herniation before seven months. Computed tomography (CT) and magnetic resonance imaging (MRI) detected a contrasted mass lesion resembling abscess formation localized in the left posterior paravertebral region. Paravertebral abscess was diagnosed and aspiration was planned under local anesthesia with ultrasonography guidance. During intervention, a needle was inserted into cavity but enough material was not aspirated. Thus, surgery was planned and a retained sponge material was found within the left paraspinal region and removed totally. The patient healed without complication.

#### Keywords

Gossypiboma; Disc Surgery; Paraspinal Abscess

DOI: 10.4328/JCAM.655

Received: 23.03.2011

Accepted: 24.03.2011

Printed: 01.05.2013

J Clin Anal Med 2013;4(3): 230-2

Corresponding Author: Süleyman Coşkun, Atatürk Üniversitesi Tıp Fakültesi Beyin ve Sinir Cerrahisi Kliniği, Erzurum, Türkiye.

T.: +905326223515 F.: +904422361228 E-Mail: dr.scoskun@hotmail.com

## Introduction

Intraoperative forgotten materials such as cottonoids and sponges widely used in lumbar disc surgery for subperiosteal muscle dissection and bleeding control is well known but rarely reported [1-5]. A review of the literature, retained sponge material following disc surgery has been rarely reported [6-9]. The incidence was reported as 0.5-1.0 per 10,000 patients [10]. Surgery is essential for the treatment of this complication. Here, we describe a case of retained surgical sponge seven months after lumbar disc surgery with importance on the CT and MRI findings.

## Case Report

A 47-year-old man presented with complaints of low back pain and sciatalgia on the left persisting for seven months. A blurred fluid leakage has been started from the wound for two months.

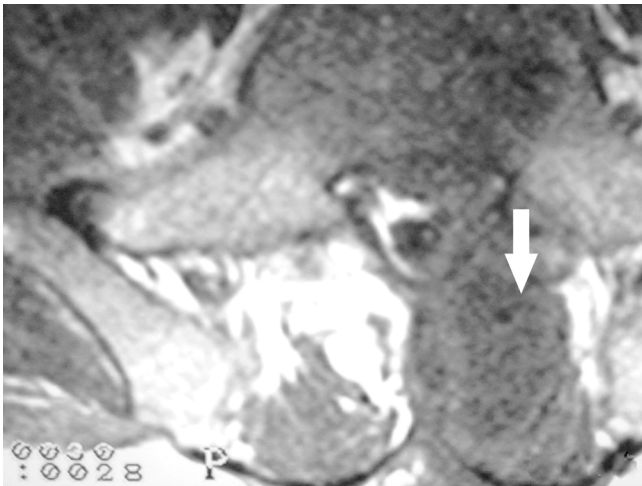


Figure 1. Axial T1-weighted magnetic resonance image shows an ellipsoid hyperintense lesion at the left paravertebral region.

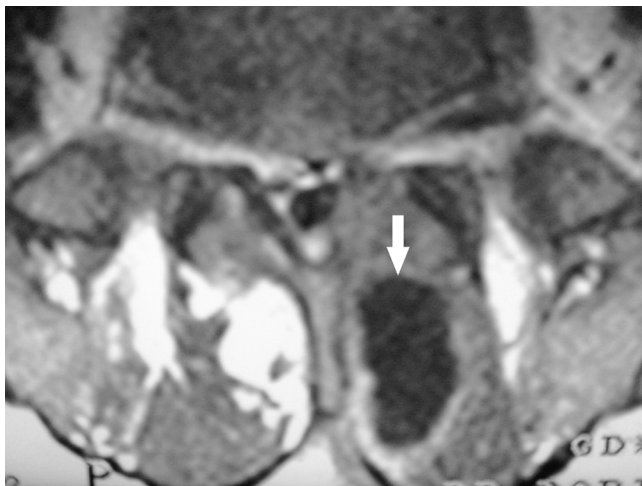

Figure 2. Axial T1-weighted magnetic resonance image with contrast medium demonstrating a ring-enhanced, hypointense ellipsoid lesion with a central hypointense nidus in the left paravertebral soft tissue at the level of L-4.

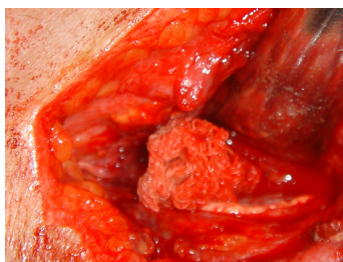


Figure 3. Sponge material is seen in the left paraspinal muscle layers.

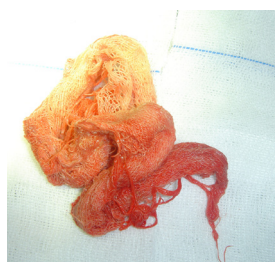

Figure 4. Extracted material is seen.

He had operated for left L4-5 intervertebral disc herniation. L4 left hemilaminectomy and discectomy was done at another medical center before nine months. The patient began to complain of severe low back pain which radiated down to the left leg in the lately. On admission, the patient was afebrile and appeared to be in good health. But, there was a fistula and cherry red like fluid leakage was detected on the incision scar area. Neurological examination and laboratory analysis were normal. X-Ray of the spine showed left L-4 hemilaminectomy defect. Lumbar CT demonstrated a ring-enhanced, 2x3 cm hyperdense ring lesion with a central hypodense nidus in the left paravertebral region. MRI of the lumbar spine showed a mass lesion, 2x3 cm in diameter, in the left posterior paravertebral region. Contrast T1-weighted MRI showed an enhanced hyperintense ring around the hypointense center suggesting an abscess formation (Fig.1). Also, the lesion appearing as hypointense encircled with a contrasted ring on T2-weighted images (Fig.2). Paravertebral soft tissue abscess was diagnosed and aspiration was planned under local anesthesia with ultrasonography guidance. During intervention, a needle was inserted into mass cavity but the needle sounded as cracked like sounds and enough abscess material was not aspirated. So, we thought that it may be a forgotten material and surgery was planned. At surgery, retained dirty sponge material was found within the paraspinal mass cavity (Fig. 3) and removed (Fig. 4). Duramater spinalis was intact. The remnant disc materials were removed and necrotic soft tissues were debrided. The wound was irrigated with saline solution and the layers were closed as usual. A drainage tube was inserted for the irrigation and drainage after postoperatively. Routine prophylactic antibiotic therapy continued until the postoperative 7th days. The sponge was cultured for aerobic and anaerobic bacteria but no bacterial growth was found. He was discharged free of pain on the 7th postoperative day.

## Discussion

Diagnosis and management of forgotten surgical sponges is very important, because serious complications may result such as abscess, adhesion, delayed wound healing, and pathological fractures [3, 7, 8, 10, 11]. Stoll reported a case of granulomatous abscess was caused by a forgotten sponge during a spine surgery 40 years previously [12]. The predisposing factors for infection in such cases are inadequate sterilization, perioperative cutaneous infection, perioperative contamination, forgotten foreign bodies (sponge, needle, cottonoids etc.), corticosteroid drugs, and spinal instrumentation [2, 3, 5, 11]. Early diagnosis, surgical removal, and appropriate antibiotic treatment (if necessary) are essential for the treatment.

Retained sponge material appears hypointense on T1-weighted MRI and hyperintense on T2-weighted MR images. Only T1-weighted MRI cannot disclose clearly the surgical sponge. T1 and T2-weighted MRI showed a folded weaving induced granuloma formation which encircled by an enhanced ring lesion within the cystic mass [13]. In our case, the core of the lesion resembled an abscess cavity, but the hyperdense appearance on CT and hypointense, almost signal void, appearance on T1-weighted imaging may be indicative of a foreign body. Foreign-body granuloma (gauzoma) induced by forgotten sponge material is not an unusual complication of posterior lumbar surgery and should be considered as a potential cause in cases of surgical wound infections. MR imaging is essential for achieve the correct differential diagnosis in such cases [14]. These relatively uncommon lesions should be differentiated from paraspinal

tumors, as well as from other postoperative complications. Although plain radiography generally gives a characteristic image due to a marking filament, the CT and especially MR findings are well known.

#### References

1. Alander DH, Stauffer ES. Gelfoam-induced acute quadriplegia after cervical decompression and fusion. *Spine* 1995; 20(8): 970-1.
2. Farina LA, Villavicencio H, Chechile G. Preoperatively recognized chronically retained pararenal gauzoma. *Int Urol Nephrol* 1995; 27(1): 33-5.
3. Ford LT: Complications of lumbar-disc surgery, prevention and treatment: local complications. *J Bone Joint Surg Am* 1968; 50(2): 418-28.
4. Friedman L, Whitecloud TS. Lumbar cauda equina syndrome associated with the use of gelfoam: case report. *Spine* 2001; 26(20): 485-7.
5. Gifford RR, Plaut MR, Mc Leary RD. Retained surgical sponge following laminectomy. *JAMA* 1973; 223(9): 1040-3.
6. Hyslop JW, Maull KI. Natural history of the retained surgical sponge. *South Med J* 1982; 75(6): 657-60.
7. Marquardt G, Retting L, Lang L, Seifert V. Retained surgical sponges, a denied neurosurgical reality? Cautionary note. *Neurosurg Rev* 2001; 24(1): 41-3.
8. Massie JB, Heller JG, Abitbol L, McPherson D, Garfin SR. Postoperative posterior spinal wound infections. *Clin Orthop* 1992; (284): 99-108.
9. Mathew JM, Rajshekhar V, Chandry MJ. MRI features of neurosurgical gossypiboma: report of two cases. *Neuroradiology* 1996; 38(5): 468-9.
10. Ramirez LF, Thisted R. Complications and demographic characteristics of patients undergoing lumbar discectomy in community hospitals. *Neurosurgery* 1989; 25(2): 226-31.
11. Yamagami T, Matsui H, Tsuji H, Ichimura K, Sano A. Effects of laminectomy and retained extradural foreign body on cauda equina adhesion. *Spine* 1993; 18(13): 1774-81.
12. Stoll A. Retained surgical sponge 40 years after laminectomy. Case report. *Surg Neurol* 1988; 30(3): 235-6.
13. Matsuki M, Matsuo M, Okada N. Case report: MR findings of a retained surgical sponge. *Radiat Med* 1998; 16(1): 65-7.
14. Turgut M, Akyuz O, Ozsunar Y, and Kacar F: Sponge-Induced Granuloma ("Gauzoma") as a Complication of Posterior Lumbar Surgery. *Neurol Med Chir* 2005; 45(4): 209-11.